copyright by Quintessence
Not for Publica

Adhesion, Layering, and Finishing of Resin Composite Restorations for Class II Cavity Preparations

Federico Ferraris, DDS
Private Practice
Alessandria, Italy

Correspondence to: Dr Federico Ferraris
Spalto Borgoglio 81, 15100 Alessandria, Italy; e-mail: info@studioff.it.

Copyright
Not for Publi

Abstract

The increasing knowledge of microhybrid composite materials has offered clinicians multiple restorative options. The use of products that guarantee a high adhesive capacity, isolation via rubber dam, and anatomic shaping with thin layering and adequate cyclic polymerization are the bases for a predictable result. Further, a finishing and polishing system that takes into account the superficial roughness and esthetic characteristics of the restorative material is the final element of a restoration that has been fabricated following correct treatment guidelines. This article aims to provide a protocol for the management of direct resin composite restorations and to discuss the correct operative sequence, particularly for the restoration of Class II cavity preparations.

(Eur J Esthet Dent 2007;2:210–221.)

copyright by Quintessence Not for Publication

Fig 1 Initial situation, before removal of the old restoration and caries.

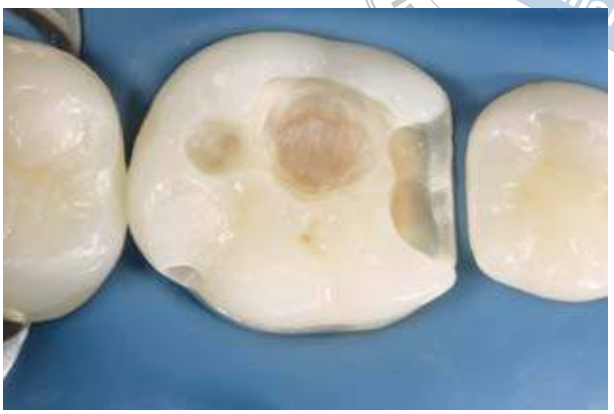

Fig 2 Cavity preparation after isolation with rubber dam followed by silver amalgam and caries removal.

A direct restoration must restore the morphology and function of a healthy tooth. The most important functions of a restorative material are as follows: to guarantee a correct marginal seal with a good internal and external adaptation to the cavity, allow a conservative cavity preparation, last over time, show biocompatibility, and present an optimal esthetic integration.

The use of resin composites for restorations in posterior teeth has greatly increased in clinical practice over the last few years.[1,2] A primary advantage of these materials is their esthetic qualities, which can satisfy even the highest patient demands.[1]

However, resin composite materials can present some problems, such as polymerization shrinkage, postoperative sensitivity, water absorption, and inconsistent marginal adhesion with the presence of microleakage. To reduce or even eliminate the phenomena responsible for these negative effects, it is highly recommended to follow precise clinical rules and establish a strict working protocol.

In Black's Class II cavity preparations, restorative factors arise that would not be present for a simple Class I cavity. This is a result of the missing interproximal walls and thus the lack of contact points with the adjacent tooth.

This article aims to provide a protocol for the general management of direct resin composite restorations, and also to demonstrate the correct operative sequence, particularly for the restoration of Class II cavities (Fig 1). The cavity preparation must be carried out with a conservative approach that accounts for the residual tooth structure, which may present excessive fragility and in such cases should be cut.[3,4]

Adhesion

To obtain a predictable result, it is important to remember that adhesion to enamel is preferable, and thus it is important, if possible, to maintain the margins in the hard tissue. However, if the margins are in dentin, it will still be possible to achieve satisfactory adhesion[5–7] as long as the biologic width is not invaded and isolation via rubber dam is carried out.

Preferably, the isolation of the working field must cover the entire quadrant start-

Copyright by Quintessence
Not for Publication

Fig 3 Finishing the margins with a medium-grain diamond tip.

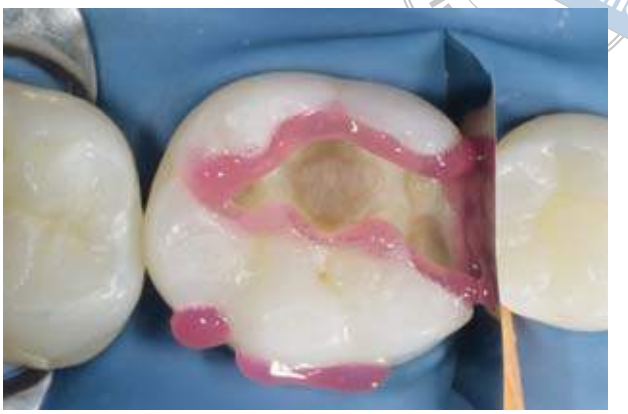

Fig 4 A metal matrix secured with a wooden wedge is used to protect the neighboring tooth from orthophosphoric acid, which is used to etch the enamel.

ing distally from the teeth that will be restored. This makes it possible to imitate the natural adjacent teeth during resin composite layering and to have good access to the interproximal zones.

Once the cavity preparation has been shaped (Fig 2), it is advisable to finish the cavity margins with a tungsten carbide bur (H390Q 314 018, Komet) or a diamond tip bur (8390 314 016, Komet). The latter is used in this protocol (Fig 3). Creating bevels on the occlusal margin of the cavity is considered to be incorrect because of the sloping of the enamel rods on the cusps.[8,9] Furthermore, during follow-ups it has been noted that this procedure offered no benefits to the restoration of a Class II preparation.[10]

To promote good adhesion, a fourth generation adhesive system is always reliable (with separate etching, primer, and bonding systems) and gives better results than other more recent adhesives,[11] particularly the latest, seventh generation.[12] The downside of these older systems is the possibility of error by the clinician because of the more laborious and time-consuming procedure compared to the modern systems.[13]

Rubber dam should be placed even before preparing the cavity in the case of amalgam filling removal, proceeded by etching with 30% to 40% orthophoshoric acid (Ena Etch, Micerium or Ultra Etch, Ultradent) first at the enamel margins (Fig 4) and then at the dentin (Fig 5), and followed finally by abundant rinsing. The etching should last for an adequate but not excessive time; some authors report an average etching time of 15 seconds.[14] Generally, the etching time for enamel should not be excessive because it provides no advantages for subsequent bond strength; however, dentin should be carefully assessed, because the more the tubules are sclerotic the longer the contact time between the orthophosphoric acid and dentin should be.[15]

To maintain a humid dentinal substrate (wet technique),[16,17] a generous amount of primer is applied—in this case an alcoholic solvent (Optibond FL, Kerr)—and after air spraying, a resinous adhesive is carefully applied to dentin and enamel and then spread with a gentle air spray. This is followed by light polymerization for an adequate time (usually 30 seconds) (Fig 6).

copyright by Not for Publication Qui

Fig 5 Dentin etching using orthophosphoric acid.

Fig 6 An alcohol solvent primer is applied along with a resinous adhesive.

Layering

To reduce the effects of polymerization shrinkage, resin composite layering can be performed using different techniques: horizontal, oblique, or three-sites.[3,18,19] This protocol used the horizontal layering technique.

Resin composite polymerization is based on many factors. An important choice regards the light-curing unit, as not all of those available on the market are capable of guaranteeing satisfactory results. Factors such as whether halogen, xenon-plasma arc, or LED lamps are used can alter the results. Other important factors include the following: the wavelength of the emitted light (should be 450 to 550 nm),[20] the intensity of the light (should be at least 450 to 650 mW/cm^2), the exposure time, the distance from the tip of the light unit to the resin composite surface, and the shade of the resin composite. Additionally, considering the polymerization shrinkage of the resin composite, modern halogen lamps (Optilux 501, Kerr) may be preferable since they offer so-called soft-start curing (ie, incremental light-curing programs), which start at a low intensity of 100 to 250 mW/cm^2, thus allowing better resin composite adaptation at the cavity margins[21,22] with minor areas of microleakage, before increasing to a standard intensity.

Various instruments can be used during layering, but a flat spatula (OP 33 DC, Deppeler) is indispensable, as is a fine-tip spatula (DD1 to DD2, Suter Dental). Bristle brushes or rubber tips can also be used to spread the resin composite after shaping.

The horizontal layering technique is easy to carry out and meets the criteria for the proper management of resin composite material.[23] The first step after adhesion is to transform the Class II cavity into a Class I cavity by reconstructing the interproximal walls. The use of a matrix is indispensable for this step, particularly a sectional matrix (Compositight, Garrison Dental Solutions) because it is easy to use and guarantees good results. In some cases, however, a circular matrix (Hawe Super Mat, Kerr) may be preferable, such as when the adjacent tooth is missing or if the extension of the cavity preparation also includes the palatal or buccal walls. The sectional matrix should be chosen in accordance with the dimension of the tooth to be restored. After it is curved and inserted, a wooden wedge

Copyright by Quintessence
Not for Publication

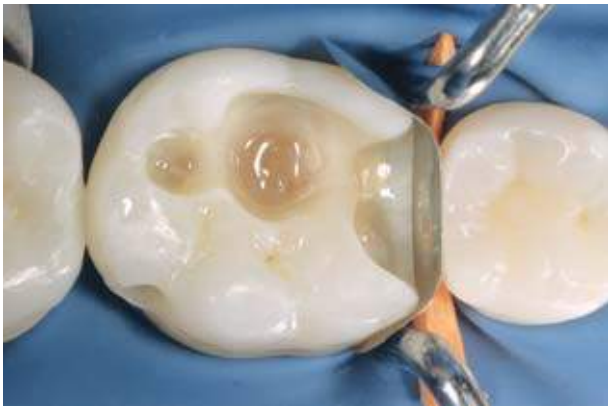

Fig 7 A sectional matrix with a wooden wedge is placed to rebuild the interproximal wall.

Fig 8 After rebuilding the mesial wall and removing the matrix, the Class II cavity is transformed into a Class I situation.

Fig 9 A thin layer of flow composite is applied to the cavity floor.

Fig 10 Microhybrid composite layering with A3.5 and A3 dentin.

is placed that presses on the matrix and thus on the walls of the two adjacent teeth. Finally, one or more rings should be inserted based on the number of walls to be restored (Fig 7). The walls are reconstructed in resin composite and polymerized, and then the ring(s) and matrix are removed. The wooden wedge can be left in place to avoid gingival bleeding and maintain the tooth position (Fig 8).

The first layer of restoration material should be a flow composite (Ena Flow, Micerium or Filtek Flow, 3M ESPE), which is applied to the cavity floor (Fig 9) to obtain a more elastic liner,[24] followed by light curing. This is not a universally approved approach; however, if resin composite fluids are used it is advisable to consider the radiopacity, which should be at least 200% aluminum to successfully carry out differential diagno-

copyright by Not for Publication Qui

Fig 11 Layering with small increases of A1 composite on the ridges and cusps.

Fig 12 Small quantities of light-polymerizing super color are applied in the sulcus to better imitate the natural teeth.

Fig 13 Microhybrid composite enamel layering.

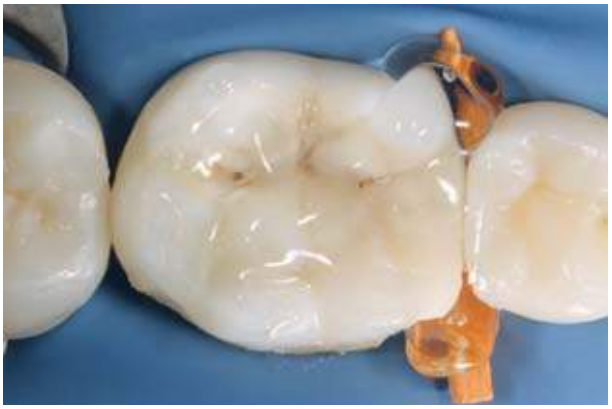

Fig 14 Final polymerization through a layer of glicerine to inhibit oxygen, which could impede complete conversion of the superficial composite.

Fig 15 Completed layering and curing before rubber dam removal.

sis with a subsequent secondary filling. The layering must be done in small increments to reduce and compensate for the effect of polymerization shrinkage.[25–27] Next, dentin-colored resin composite layers (A3 and A3.5; Enamel Plus, Micerium or Filtek Supreme, 3M ESPE) about 2 mm in thickness are applied and an initial anatomic shape is defined with a small occlusal minus (Fig 10). Once these layers have been polymerized, a dentinal composite with inferior chrome (A1) can be used to shape the marginal ridges and cusps (Fig 11). This

Copyright by Quintessence
Not for Publication

Fig 16 Restoration before finishing and polishing.

is followed by polymerization. During dentin layering, small quantities of super color (Kolor Plus, Kerr) can be used in the sulcus and polymerized to better imitate the adjoining teeth (Fig 12). The resin composite layering must simulate the enamel and recreate the final morphology of the restoration (Fig 13) so that subsequent modifications will be minimal and only the finishing and polishing procedures remain. A layer of transparent glycerine gel (Shiny Airblock, Micerium) through which a final cycle of light polymerization is carried out is applied to the restoration to obtain complete conversion of unpolymerized resin surfaces (Figs 14 to 16).[28]

Finishing and polishing

Finishing and polishing are absolutely fundamental steps of a resin composite restoration, as they limit the possible accumulation of plaque bacteria, prevent excessively quick aging, and provide brilliance and shine.[29,30] A very important element, maybe even more so than the polishing system used, is the material used for the reconstruction.[31–33] Microfilled resin composites, which were used in the past for anterior restorations, resist abrasion well[34] and are suitable for finishing and polishing, but provide low modulus and low fracture toughness with a higher rate of marginal breakdown.[35] Therefore, microhybrid materials are an excellent choice because of their ability to react to physical and mechanical stimuli while still showing suitable properties for finishing.

Rotating instruments must not be used to shape the restoration. Medium-grain (30 to 40 μ) or fine-grain (15 to 20 μ) diamond tips or carbide multiblade burs (nos. 8 to 30) can be used; however, the latter may create small gaps at the enamel-composite junction as a result of the hammering effect they produce on the surface of the restoration.[36] In any case, the diamond tips and carbide burs should be used with water cooling and a high-speed handpiece.

copyright by Quintessence Not for Publication

Fig 17 Initial finishing with a rubber or silicon tip.

Fig 18 Polishing with 3-µ diamond paste applied using a felt wheel.

Fig 19 Polishing with 1-µ diamond paste applied using a felt wheel.

Fig 20 Final finishing with 1-µ aluminum oxide paste applied with a goat-hair brush for the most convex areas.

Other useful instruments for finishing are flexible disks (Pop On XT, 3M ESPE) and abrasive strips (Sof Lex, 3M ESPE or Diamond Strip, Komet). In the interproximal zone, the use of diamond tips on a handpiece with an oscillating movement (61LRG, Kavo or Synea Profin, W&H) is effective.

For polishing, rubber tips of different hardnesses (progressing from the hardest to the softest) mounted on a handpiece are often used, as are brushes with silicon carbide polishing particles (Occlubrush, Kerr). Interestingly, however, some authors have suggested that hybrid resin composites polish well when treated with diamond paste and aluminum oxide paste.[29,37]

Copyright by Quintessence
Not for Publication

Fig 21 The finished restoration. Note the proper esthetics compared with the natural adjacent teeth.

Fig 22 Buccal view of the finished restoration.

This protocol suggests the use of silicone rubber tips (Shiny, Micerium) (Fig 17) on a low-speed handpiece, proceeded by the use of felt wheels on the same handpiece to apply 3-µ diamond paste (Shiny, Micerium) (Fig 18) followed by 1-µ diamond paste (Shiny, Micerium) (Fig 19). Finally, a goat-hair brush with 1-µ aluminum oxide paste (Shiny, Micerium) (Fig 20) should be used in the most convex areas. These materials and instruments can produce a superficial roughness that is more similar to a natural tooth (Figs 21 and 22) compared to other methods of finishing, which create major superficial roughness.[15]

copyright by Quintessence Not for Publication

Conclusion

When shaping direct resin composite restorations, it is crucial to obtain proper adhesion to the hard tissues of the tooth using reliable adhesive systems and adequate clinical procedures. The layers of the material must be thin to partially compensate for the intrinsic shrinking effect. Initially, it is preferable to rebuild the missing interproximal walls with the help of a wooden wedge and matrix, thus transforming a Class II preparation into a Class I preparation. Once the restoration has been shaped, finishing and polishing must be performed to produce a good esthetic and mechanical outcome, ensure minimal morphologic adjustments, and obtain minimal superficial roughness with the use of silicon rubber tips and brushes and diamond and aluminum oxide paste.

References

1. Jordan RE, Suzuki M. Posterior composite restorations. Where and how they work best. J Am Dent Assoc 1991;122:30–37.
2. Leinfelder KF. Posterior composite resins. J Can Dent Assoc 1989;55:34–39.
3. Dietschi D, Spreafico R. Adhesive Metal-Free Restorations: Current Concepts for the Esthetic Treatment of Posterior Teeth. Chicago: Quintessence, 1997.
4. Hinoura K, Setcos JC, Phillips RW. Cavity design and placement techniques for class 2 composites. Oper Dent 1988; 13:12–19.
5. Van Meerbeek B, Peumans M, Verschueren M, et al. Clinical status of ten dentin adhesive systems. J Dent Res 1994;73: 1690–1702.
6. Van Meerbeek B, Peumans M, Gladys S, Braem M, Lambrechts P, Vanherle G. Three-year clinical effectiveness of four total-etch dentinal adhesive systems in cervical lesions. Quintessence Int 1996; 27:775–784.
7. Fortin D, Swift EJ, Denehy GE, Reinhardt JW. Bond strength and microleakage of current dentine adhesives. Dent Mater 1994;10:253–258.
8. Glanz PJ, Nilner K, Jendresen MD, Sundberg H. Quality of fixed prosthodontics after 15 years. Acta Odontol Scand 1993;51:247–252.
9. Martin FE, Bryant RW. Acid-etching of enamel cavity walls. Aust Dent J 1984;29:308–314.
10. Willems G, Lambrecths P, Braem M, Vaneherle G. Composite resin of the 21st century. Quintessence Int 1993;24: 641–658.
11. Swift EJ Jr. Dentin/enamel adhesives: Review of literature. Pediatr Dent 2002;24:456–461.
12. Söderholm KJM, Guelmann M, Bimstein E. Shear bond strength of one 4th and two 7th generation bonding agents when used by operators with different bonding experience. J Adhes Dent 2005;7:57–64.
13. Jacobsen T, Söderholm KJM, Yang M, Watson TF. Effect of composition and complexity of denting bonding agents on operator variability—Analysis of gap formation using confocal microscopy. Eur J Oral Sci 2003;111:523–528.
14. Bryant RW. Director posterior composite resin restorations: A review. 1. Factors influencing case selection. Aust Dent J 1992;37:81–87.
15. Vanini L, Mangani F, Klimovskaia O. Conservative Restoration of Anterior Teeth. Viterbo, Italy: Acme, 2005.
16. Kanca J. Resin bonding to wet substrate. 1. Bonding to dentin. Quintessence Int 1992;23: 39–41.
17. Kanca J. Improving bond strength through acid etching of dentin and bonding to wet dentin surfaces. J Am Dent Assoc 1992;123:35–43.
18. Lutz F, Krejci I, Oldenburg TR. Elimination of polymerization stresses at the margin of posterior composite resin restorations: A new restorative technique. Quintessence Int 1986; 17:177–784.
19. Tjan AHL, Bergh BH, Lidner C. Effect of various incremental techniques on the marginal adaptation of class II composite restorations. J Prosth Dent 1992;67:62–66.
20. Cook WD. Spectral distributions on dental photopolymerization sources. J Dent Res 1982;61:1436–1438.
21. Feilzer AJ, Dooren LH, de Gee AJ, Davidson CL. Influence of light intensity on polymerization shrinkage and integrity of restoration-cavity interface. Eur J Oral Sci 1995;105:322–326.

Copyright by Quintessence
Not for Publication

22. Unterbrink GL, Muessner R. Influence of light intensity on two restorative systems. J Dent 1995;23:183–189.
23. Nikolaenko SA, Lohbauer U, Roggendorf M, Petschelt A, Dasch W, Frankenberger R. Influence of c-factor and layering technique on microtensile bond strength to dentin. Dent Mater 2004;20:579–585.
24. Van Meerbeek B, Willems G, Celis JP, et al. Assessment by nano-indentation of the hardness and elasticity of the resin-dentin bonding area. J Dent Res 1993;72:1434–1442.
25. Sakaguchi RL, Peters MC, Nelson SR, et al. Effect of polymerization contraction in composite restorations. J Dent 1992; 20:178–182.
26. Scherer W, Caliskan F, Kaim J, et al. Comparison of microleakage between direct placement composites and direct composite inlays. Gen Dent 1990;38:209–211.
27. Bertolotti RL. Posterior composite technique utilizing directed polymerization shrinkage and a novel matrix. Pract Periodont Aesthet Dent 1991;3: 53–58.
28. Bergmann P, Noack MJ, Roulet JF. Marginal adaptation with glass-ceramic inlay adhesively luted with glycerine gel. Quintessence Int 1991;22:739–744.
29. Yap AUJ, Lye KW, Sau CW. Surface characteristics of tooth-colored restoratives polished utilizing different polishing systems. Oper Dent 1997;22: 260–265.
30. Roeder LB, Tate WH, Powers JM. Effects of finishing and polishing procedures on the surface roughness of packable composites. Oper Dent 2000; 25:534–543.
31. Bouvier D, Duprez JP, Lissac M. Comparative evaluation of polishing systems on the surface of three aesthetic materials. J Oral Rehabil 1997;24: 888–894.
32. Roques YM, Joniot SB, Gregoire GL, Auther AM. Three-dimensional optical profilometry analysis of surface state obtained after finishing sequences for three composite resins. Oper Dent 2000;25: 311–315.
33. Marigo L, Rizzi M, La Torre G, Rumi G. 3D surface analysis: Different finishing methods for resin composites. Oper Dent 2001;26:562–568.
34. Zantner C, Kielbassa AM, Martus P, Kunzelmann KH. Sliding wear of 19 commercially available composites and compomers. Dent Mater 2004;20: 277–285.
35. Ferracane JL, Condon JR. In vitro evaluation of the marginal degradation of dental composites under simulated occlusal loading. Dent Mater 1999;15: 262–267.
36. Boghosian AA, Randolph RG, Jekkals VJ. Rotary instruments finishing of microfilled and small-particle hybrid composite resins. J Am Dent Assoc 1987; 115:299–301.
37. Jung M, Baumstieger M, Klimek J. Effectiveness of diamond-impregnated felt wheels for polishing a hybrid composite. Clin Oral Investig 1997;1: 71–76.